



PRESENTING CLINICAL SIGNS

History: Recently had surgery to remove an abdominal hemangiosarcoma.

DATE

1/17/23

ECHOCARDIOGRAPHIC FINDINGS

2D, M-mode, and Doppler study.

PERFORMED BY:

Tom McNeill

Left atrial size is normal. The mitral valve is normal. Left ventricular dimensions are normal. Left ventricular systolic function is normal. The aorta and aortic valve appear normal, though there is mildly increased flow velocity in the ascending aorta. Right atrial and right ventricular dimensions are normal. The tricuspid valve is normal. The pulmonary artery and pulmonic valve are normal. No shunting lesions are visualized. No pericardial effusion or cardiac masses are seen.

INTERPRETED BY

Keith Blass, DVM,
MS, DACVIM
(Cardiology)

LA - 35.6 mm
LVIDd - 39.2 mm
LVIDs - 26.6 mm
FS - 32%
RA - 28.0 mm
LVOT - 2.05 m/s
RVOT - 1.25 m/s

PATIENT

Nova Kutz

ASSESSMENT/RECOMMENDATIONS

Normal echocardiogram

SPECIES

Canine

This examination demonstrates no evidence of structural heart disease, nor does it demonstrate the presence of a cardiac neoplasm. Nova does have mildly increased flow velocity in her aorta, therefore, it's possible that she could develop a left basilar functional/innocent murmur.

No therapy is recommended based on this exam.

BREED

Labrador Retriever

A recheck echocardiogram is recommended if new physical exam and/or clinical abnormalities suggestive of cardiac dysfunction develop.

SEX

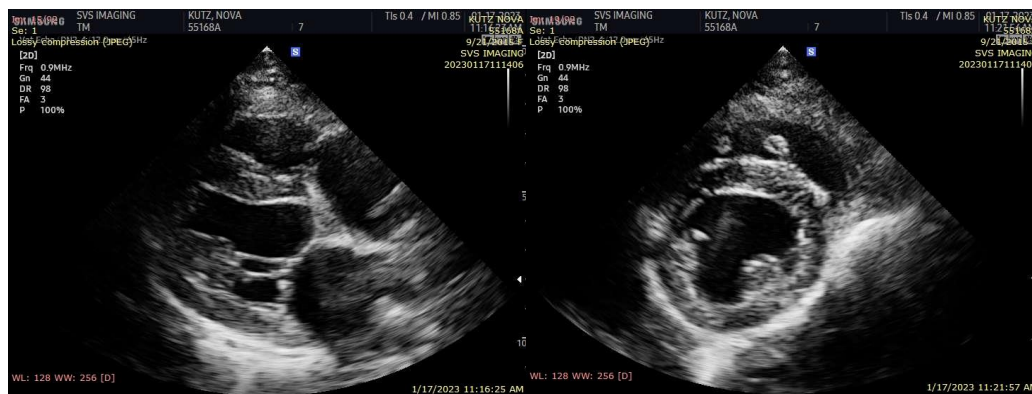
FS

AGE

7 y

WEIGHT

30.9 kg



The information and recommendations provided are based on the images presented by the referring veterinarian. No evaluation can be communicated regarding pathology that was not visible in the image/video clips provided.

HOSPITAL NAME

SVS Imaging CT

Thank you for this referral. If the clinical or image interpretation does not parallel your findings or if I can be of any further assistance please contact me.

REFERRING VET

Dr. Custead



Keith Blass, DVM, MS, DACVIM (Cardiology)

DATE KeithBlass@gmail.com
631-804-5754

1/17/23

PERFORMED BY:

Tom McNeill

INTERPRETED BY

Keith Blass, DVM,
MS, DACVIM
(Cardiology)

PATIENT

Nova Kutz

SPECIES

Canine

BREED

Labrador Retriever

SEX

FS

AGE

7 y

WEIGHT

30.9 kg

HOSPITAL NAME

SVS Imaging CT

REFERRING VET

Dr. Custead